TRUE INTERLOCKING TWINS:THE LESSONS LEARNT

Dr. Tripti Sinha*

Received 22 February 2017/ Received in revised form 10 November 2017/ Accepted 25 November 2017

Abstract

An extensive literature review reveals that though extremely rare, twin entanglement as a complication of multiple pregnancies cannot be ignored. With more pregnancies being achieved by assisted reproductive technology more cases are likely to be encountered unless strategies to anticipate and prevent its occurrence are put in place. In the worst scenario, perinatal outcome can be improved by mandatory institutional admission in late pregnancy or early labour with vigilance especially during second stage to detect slow /arrested progress during delivery of the first twin. This case highlights how this may not always be possible in low resource settings and depicts why this case had an unfortunate perinatal outcome.

Keywords: Multiple pregnancy; Twin entanglement/locking; Inter-locked twins; Perinatal outcome; Vaginal delivery; Caesarean section

Introduction

Locked twins is a rare complication of multiple pregnancies where two foetuses become interlocked during delivery. It occurs in roughly 1 in 140 to 1,000 twin deliveries and 1 in 90,000 deliveries overall.[1] With the growing incidence of multiple pregnancies due to assisted reproductive techniques, there is a strong likelihood of a commensurate increase in the incidence of locked twins also.

A case of locked twins in which neither twin could be salvaged due to late presentation is discussed to highlight the importance of patient counseling regarding regular antenatal care and institutional admission in late pregnancy or early labour to optimize the outcome of this rare but serious complication of multiple pregnancies.

Case report

A 23-year-old-primigravida from a rural area was admitted at 1.10 pm on 15/7/15 to the labour ward of Sri Krishna Medical College, Muzaffarpur, in advanced labour with arrest of the after-coming head of a baby delivering by breech *(Figure 1)*. She was about 34 weeks pregnant. Her labour pains had started the previous night but due to transport delays she reached the health facility in the advanced stage of labour.

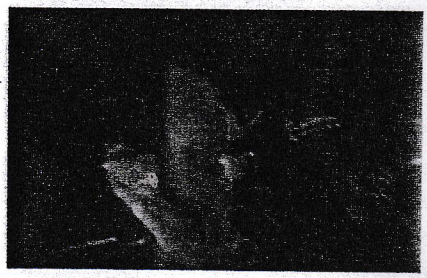

Figure 1. Arrest of after – coming head of first twin

She had routine antenatal checkups at the hospital a few times. Her last menstrual period was on 27/11/2014 and the expected date of delivery was 3/9/2015. Her investigations were within normal limits. The ultrasound report was not available at admission but her attendant informed that it was a twin pregnancy. (The report was shown later on 7/7/15, which showed two live twin foetuses; the presenting twin was in breech presentation and the second twin was in transverse lie; the expected date of delivery was 20/8/15; the placenta was anterior and liquor was adequate).

The patient on admission was in great distress with strong labour pains but vitals were stable. She was moderately pale and afebrile. Uterus was 32-34 weeks size with contracted feel. Presentation of second twin and heart sounds could not be ascertained clearly. The trunk, upper and lower limbs of the first twin was hanging at the vulva together with a loop of cord without pulsation. The cervix was fully dilated and the chin of the first twin was impacted in the vagina against the head of the second twin *(Figure 2)*. There was significant bleeding per vaginum.

Figure 2. Chin-to chin locking

Corresponding address

**Dr Tripti Sinha, Assistant Professor, Department of Obstetrics and Gynecology, Sri Krishna Medical College, Muzaffarpur, Bihar. Postal address: 705 North, Udaigiri Bhawan, Budh Marg, opposite Patna Museum, Patna-800001, Bihar, India. E-mail: triptisinha0304@gmail.com, Ph: 094310 60513/099552 40482*

A diagnosis of locked twins was made. The patient and attendants were counseled about the foetal prognosis. Emergency lower segment caesarean section was done under spinal anesthesia. The lower uterine segment was distended and thinned. The second twin was delivered abdominally by vertex at 3.42 pm on 15/7/15. An assistant then delivered the first baby vaginally; there was no cardiac pulsation in it. The abdominally delivered twin was also severely asphyxiated and could not be resuscitated. She made an uneventful recovery with routine postoperative care and was discharged on eleventh postoperative day with advice to come for postnatal review after six weeks.

Discussion

Twin interlocking is exceedingly rare in current obstetrics practice and is associated with high foetal mortality and morbidity.

Twins may only collide in the pelvis or truly interlock with each other. Such occurrences may occur in one of the four ways depending on the presentation of the first and second twin.[2]

1. Both vertices: first vertex descends into the pelvis but the second vertex gets jammed besides the thorax of the first foetus.
2. First breech /second vertex: after-coming head of first foetus gets held up at the pelvic brim by the descending head of the second one (true chin-to-chin interlocking)
3. Both breech presentations: Both breech attempts to engage together. There may be prolapse of up to four legs including loops of cord.
4. First vertex/second breech or transverse: first twin catches on some part of second twin.

This classification is very similar to that of Nissen's classification who further defined the types of twin entanglement as follows:[3]

1. Collision: The contact of any parts of one baby with its co-twin preventing engagement of either.
2. Impaction: Impact of part of one twin onto the surface of its co-twin thereby causing only partial engagement of both simultaneously.
3. Compaction: The simultaneous full engagement of leading foetal part of both twins thus filling the pelvic cavity and preventing either descent or disengagement of either.
4. Interlocking: The intimate contact of undersurface of a chin of one twin with that of its co-twin above/below the pelvic brim.

Obstetric factors purported to be implicated in the occurrence of this condition include primigravidae, small foetuses, unusually roomy pelvis, severely reduced liquor volume, mono-amniotic twins, hypertonicity and extension of the leading part.[2]

Given the fact that this is an extremely rare condition and its diagnosis occurs when the leading twin has been subjected to factors causing asphyxia loss of the first twin is almost the rule (conservatively in more than 60% reported cases).

A review of literature includes cases in which the second twin has been salvaged by a number of interventions. In recent years there has been a trend for liberal use of ultrasonography and caesarean deliveries in management of multiple pregnancies thus anticipating and obviating such devastating complications.[4] American College of Obstetricians and Gynaecologists recommends elective abdominal delivery as the preferred mode of delivery if the first twin is presenting as breech or transverse lie since the diagnosis of interlocking often occurs late in second stage when the first foetus may have suffered adverse consequences of impaction. This is usually the case in low-resource settings. This makes the case for routine monitoring of twin pregnancy with ultrasound.

If diagnosis is made late in labour when the foetuses are often dead and the case infected, management has to be individualized. Disengagement/dis-impaction under deep general anesthesia is to be attempted first failing which decapitation should be done. Zavenelli's maneuver has also been reported with successful outcome.[5] Hexoprenaline sulphate to relax the uterus to facilitate dis-impaction of locked foetal heads and secure vaginal delivery has also been reported from Johannesberg, South Africa.[6] A unique method of vaginal delivery of chin-to-chin locking was described by Kimball and Rand in 1950. The assistant held up the undelivered breech while Piper's forceps was applied to the head of the second twin. After delivery of the head of the second twin, simultaneous delivery of both twins is affected by manual traction.[7] Although in this case neither twin survived, several cases are reported in which either one or even both babies were salvaged.[8-12]

Ghosh, Chatterjee and Konar from Kolkata[13] and Sharma, Anand and Khajuria[14] from Jammu report similar dismal peri-natal outcomes as this case.

Conclusion

Twin pregnancies present with a lot of management issues. Twin-locking is best prevented by liberal resort to ante-partum and intra-partum ultrasonography, and abdominal delivery when first twin has malpresentation rather than allow labour to progress into this catastrophe.

Editor's comment

Treatment of each case must be individualized. Complication is not recognized until late in the second stage of labour. This is an unfortunate case, where both foetuses were lost due to late presentation to hospital. Foetal mortality can only be avoided by identifying the potential cases with ultrasound and timely intervention by caesarean section.

References

1. Deiry SK. Two cases of locked twins. *Br Med J* 1960; 1 (5180):1174-77.
2. Gordon R. Interlocked twins: a case report and brief review of the literature. *S Afr Med J* 1956; 30(28):661-3.
3. Nissen ED. Twins: collision, impaction, compaction, and interlocking. *Obstet Gynecol* 1958; 11(5):514-26.
4. Kurzel RB. Twin entanglement revisited. *Twin Res* 1998; 1(3):138-41.
5. Saad FA, Sharara HA. Locked twins: a successful outcome after applying the Zavanelli manoeuvre. *J Obstet Gynaecol* 1997; 17(4):366-7.
6. Sevitz H, Merrell DA. The use of a beta-sympathomimetic drug in locked twins. Case report. *Br J Obstet Gynaecol* 1981; 88(1):76-7.
7. Kimball AP, Rand PR. A maneuver for the simultaneous delivery of chin-to-chin locked twins. *Am J Obstet Gynecol* 1950; 59(5):1167-8.
8. Strickland N, Saneman P. Locked twins. Report of 3 cases. *Obstet Gynecol* 1967; 29(2):211-2.
9. Adams DL, Fetterhoff CK. Locked twins. A case report. *Obstet Gynecol* 1971; 38(3):383-5.
10. Pandey MR, Ghimire P, Ghimire P. Successful vaginal delivery of locked twins in a tertiary care centre of western region of Nepal. *Nepal Journal of Medical Sciences* 2014; 3(1):74-75.
11. Veena P, Chaturvedula L. Two rare complications of twin gestation manifesting as arrest of descent in second stage of labour. *Int J Adv Med Health Res* 2016; 3(2):94-96.
12. Borah T, Das A. Locked twins: a rarity. *Ann Med Health Sci Res* 2012; 2(2):204-5.
13. Ghosh B, Chatterjee DP, Konar M. Interlocking in twin pregnancy (A case report). *JOGI* 1976; 155-157.
14. Sharma S, Anand A, Khajuria R. Interlocked twins: A case report. *JK Sciences* 2014; 16(4):188-189.

0612-2321542
0612-2320539

THE PATNA JOURNAL OF MEDICINE

ESTD : 1925

A monthly Publication Under The Joint Auspices of the Bihar State Branch of the Indian Medical Association and Patna Medical Association

Office Address
I.M.A. BUILDING
DR. A.K.N. SINHA PATH,
SOUTH - EAST GANDHI MAIDAN
PATNA - 800 004.
E -mail : imapjm@gmail.com

Ref. No. P/17/2018 *Date.* 08.03.2018

To,
Dr. Tripti Sinha
Assistant Professor,
Department of Obstetrics & Gynaecology,
Sri Krishna Medical College & Hospital
Muzaffarpur.

Dear Sir / Madam,

With pleasure, we have to inform you that your article entitled **"RUPTURE UTERUS : REVIEW OF MANAGEMENT IN A MEDICAL COLLEGE IN NORTH BIHAR "** has been accepted for publication in the Patna Journal of Medicine.

Thanking you,

Yours sincerely,

(Amar Kant Jha 'Amar')
Editor

Rupture Uterus: Review of management in a medical college in North Bihar

Introduction:

The obstetrical calamity- uterine rupture- continues to contribute significantly to maternal and peri-natal morbidity and mortality especially in less and least developed countries and regions of the world. It remains uneradicated even in developed countries due to rising Cesarean section rates. (1)

The present study reviews the causes, the management strategies adopted there and the maternal and fetal outcome of uterine rupture in patients admitted to a medical college in North Bihar which predominantly serves a rural population.

Material and methods:

The study is a retrospective analysis of the case notes of patients of uterine rupture admitted to the labor ward of Sri Krishna Medical College Hospital, Muzaffarpur in Bihar. The salient points in the demographic and obstetric profile were collected and analyzed to give an indication of the etiological factors for uterine rupture in this predominantly rural population often living far from any primary or higher health care facilities. The definitive surgery performed and maternal and fetal outcomes were noted also.

Results:

There were 31 cases of uterine rupture during the period 01/04/2016-31/03/2017 in this institution with an average annual delivery rate of 9000-11000(prevalence 0.31 %). Although in terms of percentage this may not appear significant numerically these cases cannot be ignored because of the impact upon the survival, quality of life and future reproductive aspirations of these women.

Table 1 summarizes age, religion and parity profile of the cases. There were no teenage pregnancies, 21 cases were between 20-30 years (67.74%), 9 were between 31-40 years (29.03%) and 1 was above 40 years (3.23%). There was 1 case documented as primigravida (3.23%) , 23 were multips (74.1%) and 7 were grand multipara (22.58%). 24(77.41%) women were Hindus and 7(22.58%) were Muslims. All were living in rural areas from where they were referred to the tertiary centre. 12(38.7%) cases had previous cesarean section, had gone into spontaneous labor and were admitted to the hospital late whereas in others (n=19, 65.5%) obstructed labor was the etiological factor for uterine rupture.

Table 2 shows the type of surgical interventions done in the 31 cases of rupture of uterus studied in our institution.12 cases (38.7%) had only repair of uterine rent done, 10 cases (32.23%)had rent repair combined with bilateral tubectomy, 8(25.8%) had subtotal hysterectomy and only I(3.23%) had total hysterectomy. Among those who had rent repair, either alone or combined with sterilization operation 11(35.48%) had rupture of unscarred uterus; 20 (66.52%) had a uterine scar which had ruptured or had dehiscence. In 7(25.58%) cases with only uterine repair the future reproductive potential was preserved by omitting sterilization operation procedure after counseling about the risks in future pregnancy and labor.

All cases which had subtotal hysterectomy were cases in which the rupture occurred in an unscarred uterus. The single case in which total hysterectomy had been performed had a cesarean section previously. It was not documented in the case notes why the uterus could not be preserved in this case.

The post-operative period of all cases was largely uncomplicated without any major c omplications. The women were discharged in a satisfactory condition.

The peri-natal outcome was extremely poor. There were 26(83.87%) stillbirths, 4(12.9%) were alive but asphyxiated and only 1 baby was born in a good condition (3.23%).

Discussion:

A WHO systematic review of maternal morbidity and mortality (1) cites the incidence of uterine rupture in an unselected population in less and least developed countries as 0.016%-0.30%(community – based figures) and 0.012%- 2.9% (hospital-based figures)-overall 0.1%-1%. In developed countries the incidence is 1% in women with scarred uterus and <1/10,000 in those with unscarred uterus (overall <1/1000, 0.1%).The incidence in this study is similar to that of other countries in this region of the world like Pakistan and Nepal and in other government hospitals of India (2, 3,4,5).

Our observations regarding the epidemiological profile and risk factors of the women in these studies are also similar to that of the profile of women having rupture uterus in our series. Risk factors for rupture of uterus remains the same as before: poor antenatal care and delayed decision- making regarding abdominal delivery especially when labor was initially being managed at the primary health care setting initially. The incidence is rising owing to the compounding effect of the rising cesarean section rates and misoprostol for induction of labor in uncontrolled dosages in different parts of the world (6) This has assumed worrying proportions in both urban and rural areas. Lowering the incidence of uterine rupture, therefore, include strategies to reduce primary cesarean section rates such as using a simplified partogram or a even more simple clinical tool like the one suggested by Debdas (7) which can be utilized easily by ANMs and nurses at the periphery. Cases of prolonged labor would be referred timely to FRUs and higher centers with facilities for abdominal delivery before they ended up in obstructed labor or rupture uterus in the worst scenario.

In our series uterus was conserved in 70.93% cases and sterilization operation was performed in only 32.23% cases leaving both menstrual and reproductive function intact although with risk of uterine rupture in subsequent pregnancy and labor. Hysterectomy –subtotal and total- which compromised both menstrual and reproductive functions was done in 29.3% cases. This is different from the management strategies in other series in which hysterectomy rates varied from 32%, 41.51%, 46% and 55% respectively. (3,4,8, 9).None of the cases required associated surgeries like bladder repair , repair of vaginal vault rents or internal iliac artery ligation to control postpartum hemorrhage as was reported in the series compiled by Sahu(4) .

The choice of operation performed is dependent largely on the findings at operation-the site of the rent and the extent of damage to the adjacent structures .Another important consideration is the couple's intention of whether or not to retain the woman's reproductive and / or menstrual potential. These issues need to be incorporated as part of the pre-operative counseling and informed consent procdureso that there are no medico-legal disputes subsequently.

Conclusion:

Rupture uterus is a completely avoidable obstetric calamity. Prevention does not require high grade expensive technology but down –to- earth interventions like simple clinical tools. minimizing delay in patient referral and transport to FRUs and higher centers with facilities for abdominal delivery , good monitoring of labor in cases with previous cesarean deliveries so that VBAC becomes a safe and viable option for delivery and, most importantly, thoughtfulness before performing the primary cesarean section rather than doing it for flimsy, unsubstantiated indications. Prevention of grand multiparity by incorporating contraceptive counseling at every stage when the woman and her husband interact with the health care

system needs to be stressed repeatedly to hospital and community health care providers from the time of commencement of their training.

References

1. Hofmeyr Justus, Lale Say, Giilmezoglu Metin. WHO systematic review of maternal mortality and morbidity: the prevalence of uterine rupture BJOG Sept 2005(112):1221-1228

2. Qazi Qudira, Akhtar Zubaida, Khan I Kamran, Khan Amer Hayat Woman health:Uterine rupture , its complications and management in a teaching hospital, Bannu, Pakistan.. A Journal of Clinical Medicine 2012 Vol 7(No. 1):49-53

3. Sunitha K., Indira I.and Suguna P. Clinical Study of Rupture Uterus - Assessment of Maternal and Fetal Outcome *IOSR Journal of Dental and Medical Sciences (IOSR-JDMS) e-ISSN: 2279-0853, p-ISSN: 2279-0861.Volume 14, Issue 3 Ver. VI (Mar. 2015), PP 39-45*

4. Sahu *Latika.* A 10 year analysis of uterine rupture at a teaching institution *J Obstet Gynecol India Vol. 56, No. 6: November/ December 2006 Pg 502-506*

5. Padhye SM. Rupture of the pregnant uterus- a 20 year review . Kathmandu University Medical Journal 2005 Vol 3(11) pg 234-238

6. Ezechi O, Kalu B, Njokamma F,Okaka G. Vaginal misoprostol IOL: a Nigerian hospital experience.J Obstet Gynecol 2004;24(3):239-242).

7. Veena L,Sarojini,AnagondanahalliPrathima, Prakash, Suchitra. Study to compare betweenpaperless partogram and modified WHO partogram in management of labor. Int J of Reprod , Contracept, Obstet andGynecol 2018 Jan; 7(1):99-103)

8. Rashmi, Radhakrishnan G, Vaid NB, Agarwal N. Rupture uterus- Changing Indian scenario. J Indian Med Assoc. 2001; 99(11):634-7

9. Diab AE. Uterine rupture in Yemen. Saudi Medical Journal.2005;26(2):264-269

Table 1: Demographic profile of cases of rupture uterus

Patient characteristic		Number (n)	Percentage (%)
Age (Years)	<20	0	0
	20-30	21	67.74
	31-40	9	29.03
	>40	1	3.23
Religion	Hindu	24	77.41
	Muslim	7	22.58
Parity	primip	1	3.23
	G2-G4	23	74.1
	Grand multip	7	22.58